

## The intercrystal line determined by palpation is not a reliable anatomical landmark for neuraxial anesthesia

## La ligne de Tuffier identifiée par palpation n'est pas un repère anatomique fiable pour l'anesthésie neuraxiale

Clarita B. Margarido, MD, PhD · Rafeek Mikhael, MD, PhD ·  
Cristian Arzola, MD · Mrinalini Balki, MD ·  
Jose C. A. Carvalho, MD, PhD

Received: 4 August 2010 / Accepted: 15 November 2010 / Published online: 3 December 2010  
© Canadian Anesthesiologists' Society 2010

### Abstract

**Purpose** The radiological intercrystal line (Tuffier's line) usually intersects the spine at the L4-L5 interspace. The intercrystal line determined by palpation may be used erroneously as a surrogate for the true radiological Tuffier's line. We studied term pregnant women to establish the level at which a transverse line connecting the superior aspects of the iliac crests, as determined by palpation, intersects the lumbar spine, as assessed by ultrasound.

**Methods** Term pregnant women were recruited, with the exception of those with scoliosis or previous spinal surgery. With the subjects in the sitting position, the attending anesthesiologist palpated and marked the superior aspects of the iliac crests bilaterally. One of the investigators, blinded to the markings, performed a lumbar spine ultrasound scan to identify the lumbar interspaces. Each interspace was marked on the patient's back. The bilateral markings were then revealed, and a line connecting them was drawn on the patient's back. This line and the markings of the interspace levels were plotted on a transparent sheet.

**Results** Forty-five women were studied. The palpated intercrystal line was located above the L4-L5 interspace in all of the women. The median level of intersection was immediately below the L2-L3 interspace, with a range from immediately above L1-L2 to immediately above L4-L5.

There was a low positive correlation between the level of intersection and the body mass index ( $r = 0.32$ ;  $P = 0.03$ ).

**Conclusions** In pregnant women at term, the intercrystal line determined by palpation does not correspond to the Tuffier's line determined radiologically, and it may intersect the spine at up to three interspaces higher.

### Résumé

**Objectif** La ligne de Tuffier radiologique croise en général la colonne vertébrale à l'espace entre L4 et L5. La ligne de Tuffier telle que déterminée par palpation pourrait être utilisée à tort comme substitut de la véritable ligne de Tuffier radiologique. Nous avons étudié des parturientes à terme afin d'établir le niveau auquel une ligne transverse connectant les aspects supérieurs des crêtes iliaques, telle que déterminée par palpation, croise la colonne lombaire, telle qu'évaluée par échographie.

**Méthode** Des parturientes à terme ont été recrutées, à l'exception des patientes souffrant de scoliose ou ayant subi une chirurgie rachidienne par le passé. En plaçant les patientes dans une position assise, l'anesthésiologiste a palpé et marqué les aspects supérieurs des crêtes iliaques de façon bilatérale. L'un des chercheurs, ne voyant pas les marques, a réalisé une échographie de la colonne lombaire afin d'identifier les espaces interlombaires. Chaque espace a été marqué sur la peau du dos des patientes. Les marques bilatérales ont ensuite été révélées, et une ligne les connectant a été dessinée. Cette ligne et les marques des espaces interlombaires ont été reproduites sur une feuille transparente.

**Résultats** Quarante-cinq femmes ont été étudiées. La ligne de Tuffier telle que déterminée par palpation était située au-dessus de l'espace interlombaire L4-L5 chez

C. B. Margarido, MD, PhD (✉) · R. Mikhael, MD, PhD ·  
C. Arzola, MD · M. Balki, MD ·  
J. C. A. Carvalho, MD, PhD

Department of Anesthesia and Pain Management, Mount Sinai Hospital, University of Toronto, 600 University Avenue, Room 781, Toronto, ON M5G 1X5, Canada  
e-mail: claritamargarido@hotmail.com

toutes les patientes. Le niveau médian d'intersection était situé immédiatement en dessous de l'espace interlombaire L2-L3, les marques allant d'un point immédiatement supérieur à L1-L2 à un point immédiatement supérieur à L4-L5. Une faible corrélation positive a été observée entre le niveau d'intersection et l'indice de masse corporelle ( $r = 0,32$ ;  $P = 0,03$ ).

**Conclusion** Chez les parturientes à terme, la ligne de Tuffier telle que déterminée par palpation ne correspond pas à la ligne de Tuffier déterminée par radiologie, et elle pourrait croiser la colonne à un niveau intervertébral situé jusqu'à trois vertèbres plus haut.

The identification of the intervertebral level is an essential component of epidural and spinal anesthesia. The spinal level at which neuraxial anesthesia is performed contributes to the extent of the blockade in both techniques. More importantly, spinal anesthesia should be performed below the level of the conus medullaris to minimize the risk of spinal cord trauma.<sup>1,2</sup> The clinical identification of the interspace level, which typically relies on the palpation of the iliac crests to determine the landmark, is largely inaccurate. Broadbent *et al.*<sup>3</sup> demonstrated that anesthesiologists could identify a particular lumbar interspace correctly by palpation in only 29% of cases; they were one, two, three, or four spaces higher than the correct space (assessed by magnetic resonance imaging) in 51%, 15%, 2%, and 1% of cases, respectively.

The explanation for this discrepancy may reside in the inappropriate association between the intercrystal line determined by palpation and Tuffier's line.<sup>1</sup> Tuffier's line is the transverse line connecting the superior aspects of the iliac crests on an *x-ray*, and it most commonly intersects the spine at the level of the L4 vertebral body or the L4-L5 interspace. However, there is substantial inconsistency in the literature regarding the level of intersection.<sup>3-5</sup> Due to differences related to gender, height, and body mass index (BMI), Tuffier's line has been reported to intersect the vertebral column anywhere from the L3-L4 to the L5-S1 intervertebral discs.<sup>3-6</sup> In men, Tuffier's line most often intersects the body of L4 or its inferior endplate, whereas in women, it most commonly intersects the body of L5 or its superior endplate.<sup>5</sup> It is imperative to highlight that Tuffier's line is a radiological landmark that does not take into account the patient's body habitus or positioning.

Ultrasound imaging has become an increasingly popular procedure among anesthesiologists to facilitate neuraxial anesthesia.<sup>7-13</sup> The use of bedside spinal ultrasound scanning can overcome most of the above-mentioned difficulties in identifying the vertebral interspace accurately, and it has proven to be a valuable clinical tool to improve the accuracy

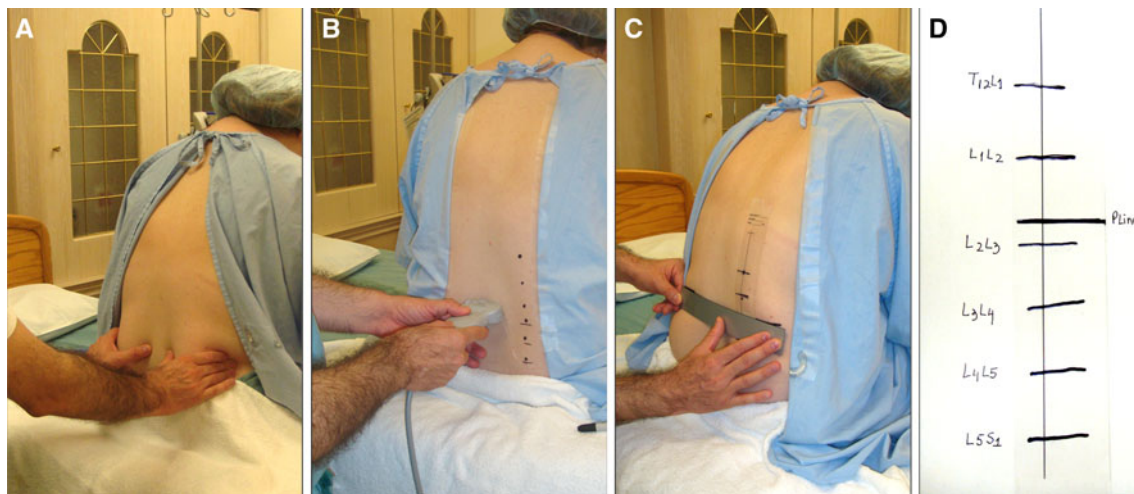
of spine assessment.<sup>10,14</sup> This is particularly advantageous in pregnant women in whom several factors can potentially interfere with the palpation of lumbar spine landmarks: hyperlordosis, progressive pelvic rotation over the long axis of the spinal column, and weight gain. These conditions may position the intercrystal line in a more cephalad relationship with the vertebral column.

The present study was conducted with the aid of ultrasound to determine the level at which the intercrystal line determined by palpation intersects the lumbar spine in term pregnant women. We hypothesized that this line intersects the lumbar spine in this population at a more cephalad segment than the L4-L5 interspace.

## Methods

This prospective observational study was conducted during the period December 2009-May 2010 after approval by the Mount Sinai Hospital Research Ethics Board. After obtaining written informed consent, we enrolled pregnant women at term who had been admitted to our labour and delivery unit. We excluded women with known scoliosis or previous spinal surgery.

With the subject in the sitting position, the attending anesthesiologist palpated and marked the superior aspects of the iliac crest bilaterally (Fig. 1A). The markings were then covered by taping the subject's gown onto her back. One of the investigators, blinded to these markings, performed a spinal ultrasound scan to locate all of the lumbar interspaces from T12-L1 to L5-S1. A portable ultrasound system equipped with a 5-2 MHz curved array probe (Sonosite MicroMaxx<sup>TM</sup> Canada Inc., Markham, ON, Canada) was used. After locating the sacrum to ensure that no interspace was missed, the interspaces were initially identified in the paramedian longitudinal plane. However, in order that the markings would reflect the optimal needle insertion points for midline punctures, the final marking of the interspaces on the subject's back was completed after scanning in the transverse plane, (Fig. 1B). Upon completion of the scanning, the iliac crest markings were revealed, and a horizontal line connecting the two markings, i.e., the palpation line (Pline) was drawn on the subject's back (Fig. 1C). The interspaces and the Pline were transcribed on a transparent sheet placed on the subject's back (Fig. 1D). The distance between any two consecutive interspaces was then divided into three equal segments. Starting from the L5-S1 interspace and counting cephalad, 15 segments were marked and numbered sequentially from 1 (most caudal) to 15 (most cephalad). This division in segments was arbitrary, and it was meant solely to provide a visual idea of the intersection level with respect to the upper and lower adjacent interspaces. In this



**Fig. 1** (A) The attending anesthesiologist palpated the superior aspects of the iliac crest bilaterally. (B) The investigator, blinded to the markings, performed a lumbar spine ultrasound scanning to locate and mark all of the lumbar interspaces. (C) After unblinding the two

iliac crest markings, the investigator drew a line connecting them. (D) The intercrystal line and the interspaces were plotted on a transparent sheet taped onto the subject's back

way, the marked level could be assessed as being closer to one interspace or equidistant from two consecutive interspaces. Demographic data were recorded in the form of height, weight, BMI, gravidity, parity, and gestational age.

#### Statistical analysis

Descriptive statistics were calculated using mean and standard deviation for continuous variables; otherwise percentage was used. The level of intersection of the intercrystal line with the spinal segments was depicted in a frequency histogram. We calculated Spearman's correlations to determine if there was any association between basic anthropometric variables (age, height, weight, and BMI) and the intercrystal line assessment. Statistical significance was considered at  $P \leq 0.05$ .

In order to calculate the sample size, the null hypothesis was based on the study by Kettani *et al.*,<sup>6</sup> in which the intercrystal line was found to intersect the spine above L4-L5 in 63.7% of the pregnant women. In that study, the interspaces were identified by palpation from C7 to the sacrum. Our alternate hypothesis was based on the study by Chakraverty *et al.*,<sup>15</sup> in which they determined, by means of fluoroscopy, that the palpated intercrystal line in the female subgroup was above L4-L5 in 85.7% of cases. Assuming a two-sided type I error of 5% and a type II error of 10%, a sample size of 40 subjects with 90% power was needed to demonstrate that the intercrystal line intersects the lumbar spine in term pregnant women in a more cephalad segment than the L4-L5 interspace. To account for a 10% loss due to potential withdrawals and technical failures, we increased the target sample size to 45 subjects.

The statistical analysis was performed with SPSS version 17.0 (SPSS Inc., Chicago, IL, USA).

#### Results

Sixty-seven women were approached for the study; 18 declined, 49 were enrolled, and four were excluded after enrolment for various reasons unrelated to the study method. Forty-five women completed the study.

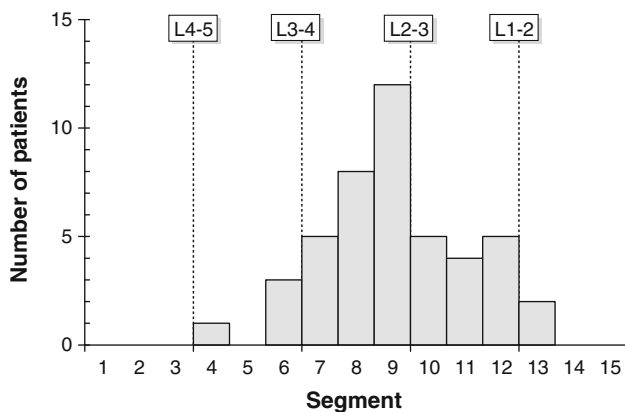
The women's demographics are presented in Table 1.

The intercrystal line was located above the L4-L5 interspace in all of the 45 women (100%, 95% confidence intervals [CI]: 92.1-100%). The intersection was at a level higher than L3-L4 in 41 women (91.1%, 95% CI: 78.8-97.5%) and higher than L2-L3 in 16 women (35.5%, 95% CI: 21.9-51.2%) (Fig. 2). Segment 9 (located immediately below the L2-L3 interspace) was the median segment at which the Pline intersected the spine, with a range from

**Table 1** Descriptive statistics of patients' characteristics

Variable	$n = 45$
Age (yr)	34.4 (4.4)
Height (cm)	163.4 (6.9)
Weight (kg)	80.9 (14.8)
Body mass index ( $\text{kg}\cdot\text{m}^{-2}$ )	30.3 (5.3)
Nulliparous (%)	46.6
Multiparous (%)	53.4
Gestational age (weeks)	38.9 (1.8)

Results are presented as mean (standard deviation) or %



**Fig. 2** The frequency of spinal segments intersected by the palpated intercrystal line

**Table 2** Spearman’s correlation coefficients between the levels of intersection and patients’ characteristics

Variable	Correlation coefficient	95% Confidence Interval	P value
Height (cm)	-0.22	-0.48-0.08	0.14
Weight (kg)	0.18	-0.12-0.45	0.24
Body mass index (kg·m <sup>-2</sup> )	0.32	0.03-0.56	0.03
Gestational age (weeks)	-0.06	-0.34-0.24	0.71

segment 4 (immediately above L4-L5) to segment 13 (immediately above L1-L2).

There was a low positive correlation between the level of intersection and BMI ( $r = 0.32$ ;  $P = 0.03$ ) but not with the other variables (Table 2).

**Discussion**

Our results demonstrate that the intercrystal line determined by palpation intersects the lumbar spine in term pregnant women at a more cephalad level than the L4-L5 interspace, which is the intersection level of Tuffier’s line. The median level of intersection was immediately below the L2-L3 interspace, and the intersection levels ranged from immediately above the L1-L2 interspace to immediately above the L4-L5 interspace.

Our findings reinforce the thinking that bedside spinal ultrasound, which has recently become widely available in the clinical setting, may be advantageous in determining the exact level of the puncture.<sup>8,9,14</sup> The use of bedside spinal ultrasound may take us one step closer to the safer practice of neuraxial anesthesia by helping to avoid direct trauma to the spinal cord, a rare but preventable complication.<sup>2</sup> It is important to highlight, however, that it is not

possible to visualize the conus medullaris with the current technology; therefore, there is still the possibility of trauma in cases of low lying spinal cords.

Our results concur with those in a study by Kettani *et al.*,<sup>6</sup> in which the palpated intercrystal line intersected the spine at the anticipated level (vertebral body of L4 or L4-L5 interspace) in only 29.7% of the patients. They found the intersection point below the expected level in 6.6% of the cases and above the expected level in 63.7% of the cases. They also demonstrated a significant correlation between the level and the patient’s weight and BMI. However, the authors identified the corresponding vertebral level by counting the spinous processes from C7, which is a method that may not be highly accurate.<sup>6</sup> Besides, the result may not always be reproducible, as the spinous processes may not be easily palpable in all women, especially those who are pregnant and/or overweight.

Our results are in contrast with those from a recent study by Pysyk *et al.*,<sup>13</sup> in which they observed, by means of ultrasound, that the palpated intercrystal line intersected the spine above the L3-L4 level in only 13% of subjects, mostly taller individuals and males. The differences between our study and theirs could be attributed to several factors, including the changes in body habitus and spine curvature associated with pregnancy in our patient population. Additionally, Pysyk *et al.* used only the longitudinal paramedian approach for scanning, and they approximated the level of intersection to the immediately cephalad or caudad interspace. This approach may have skewed their data in the more caudad interspaces. Most importantly, a potential source of bias in their study could be having used a single unblinded investigator to assess both the palpated intercrystal line and the vertebral levels ascertained by ultrasound.

In conclusion, the intercrystal line determined by palpation in pregnant women at term does not correspond to the classic Tuffier’s line, which is a radiological concept. Therefore, it is an inaccurate surrogate for the L4-L5 vertebral interspace. In this population, the palpated intercrystal line most frequently intersects the spine just below the L2-L3 vertebral interspace, but it may intersect the spine from just above L4-L5 to just above L1-L2. This information should be taken into consideration while performing neuraxial anesthesia, particularly the spinal and combined spinal-epidural techniques.

**Acknowledgement** The authors thank Kristi Downey MSc, Perinatal Anesthesia Research Coordinator, Department of Anesthesia and Pain Management, Mount Sinai Hospital, Toronto, for her valuable help with patient recruitment and organization of the study database.

**Funding** Departmental.

**Conflict of interests** None declared.

## References

1. Lirk P, Hogan Q. Spinal and epidural anatomy. In: Wong CA (Ed). *Spinal and Epidural Anesthesia*, 1<sup>st</sup> ed. Chicago: McGraw-Hill Companies Inc.; 2007: 1-27.
2. Cook TM, Counsell D, Wildsmith JA; *Royal College of Anaesthetists Third National Audit Project*. Major complications of central neuraxial block: report on the Third National Audit Project of the Royal College of Anaesthetists. *Br J Anaesth* 2009; 102: 179-90.
3. Broadbent CR, Maxwell WB, Ferrie R, Wilson DJ, Gawne-Cain M, Russell R. Ability of anaesthetists to identify a marked lumbar interspace. *Anaesthesia* 2000; 55: 1122-6.
4. Quinmell RC, Stockdale HR. The use of in vivo lumbar discography to assess the clinical significance of the position of the intercrystal line. *Spine (Phila Pa 1976)* 1983; 8: 305-7.
5. Snider KT, Kribs JW, Snider EJ, Degenhardt BF, Bukowski A, Johnson JC. Reliability of Tuffier's line as an anatomic landmark. *Spine (Phila Pa 1976)* 2008; 33: E161-5.
6. Kettani A, Tachinante R, Tazi A. Evaluation of the iliac crest as anatomic landmark for spinal anaesthesia in pregnant women (French). *Ann Fr Anesth Reanim* 2006; 25: 501-4.
7. Watson MJ, Evans S, Thorp JM. Could ultrasonography be used by an anaesthetist to identify a specified lumbar interspace before spinal anaesthesia? *Br J Anaesth* 2003; 90: 509-11.
8. Arzola C, Davies S, Rofael A, Carvalho JC. Ultrasound using the transverse approach to the lumbar spine provides reliable landmarks for labor epidurals. *Anesth Analg* 2007; 104: 1188-92.
9. Carvalho JC. Ultrasound-facilitated epidurals and spinals in obstetrics. *Anesthesiol Clin* 2008; 26: 145-58.
10. Balki M, Lee Y, Halpern S, Carvalho JC. Ultrasound imaging of the lumbar spine in the transverse plane: the correlation between estimated and actual depth to the epidural space in obese parturients. *Anesth Analg* 2009; 108: 1876-81.
11. Borges BC, Wieczorek P, Balki M, Carvalho JC. Sonoanatomy of the lumbar spine of pregnant women at term. *Reg Anesth Pain Med* 2009; 34: 581-5.
12. Margarido CB, Arzola C, Balki M, Carvalho JC. Anesthesiologists' learning curves for ultrasound assessment of the lumbar spine. *Can J Anesth* 2010; 57: 120-6.
13. Pysyk CL, Persaud D, Bryson GL, Lui A. Ultrasound assessment of the vertebral level of the palpated intercrystal (Tuffier's) line. *Can J Anesth* 2010; 57: 46-9.
14. Grau T, Leipold RW, Conradi R, Martin E, Motsch J. Efficacy of ultrasound imaging in obstetric epidural anesthesia. *J Clin Anesth* 2002; 1: 169-75.
15. Chakraverty R, Pynsent P, Isaacs K. Which spinal levels are identified by palpation of the iliac crests and the posterior superior iliac spines? *J Anat* 2007; 210: 232-6.